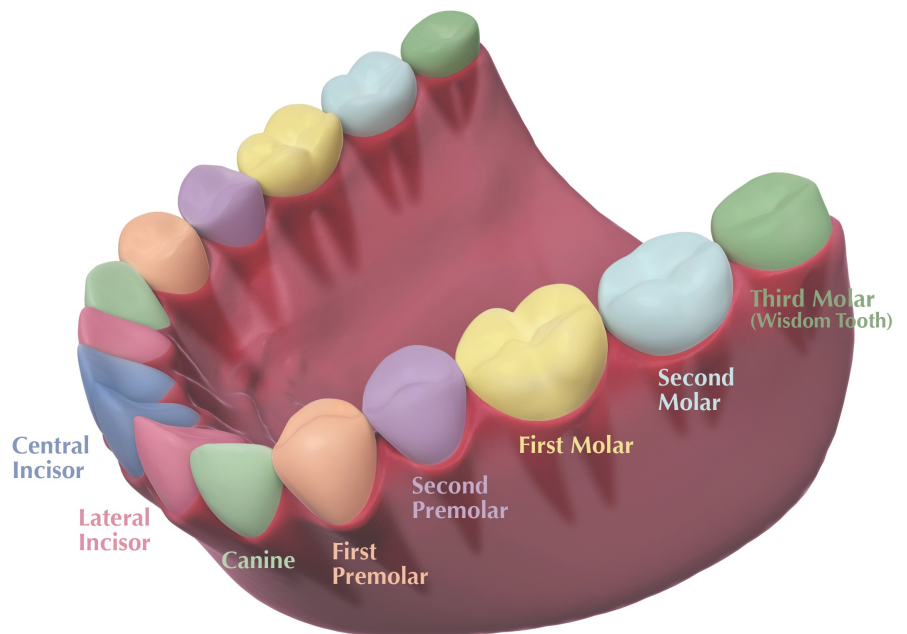


Teeth

- 1-Central Incisor
- 2-Lateral Incisor
- 3-Canine
- 4-First Premolar
- 5-Second Premolar
- 6-First Molar
- 7-Second Molar
- 8-third Molar (wisdom tooth)



Tooth position and function

Incisor teeth are your four front teeth (Two at the top, 2 at the bottom). They are used for cutting food using their sharp edges

Canine teeth are very strong teeth used for tearing and holding food. They are a different shape to the incisor teeth and have a cusp or pointed edge.

Pre-molar teeth are used for crushing food and are shaped with 2 cusps usually. They are very different in size and shape to the incisor and canine teeth.

Molar teeth are further back in the mouth and are used for grinding and chewing food. They have a large chewing surface and can have as many as five cusps.

Anterior teeth are located in the front of the mouth (incisors, canine)

Posterior teeth are found further back in the mouth (premolars and molars)

Parts of the tooth

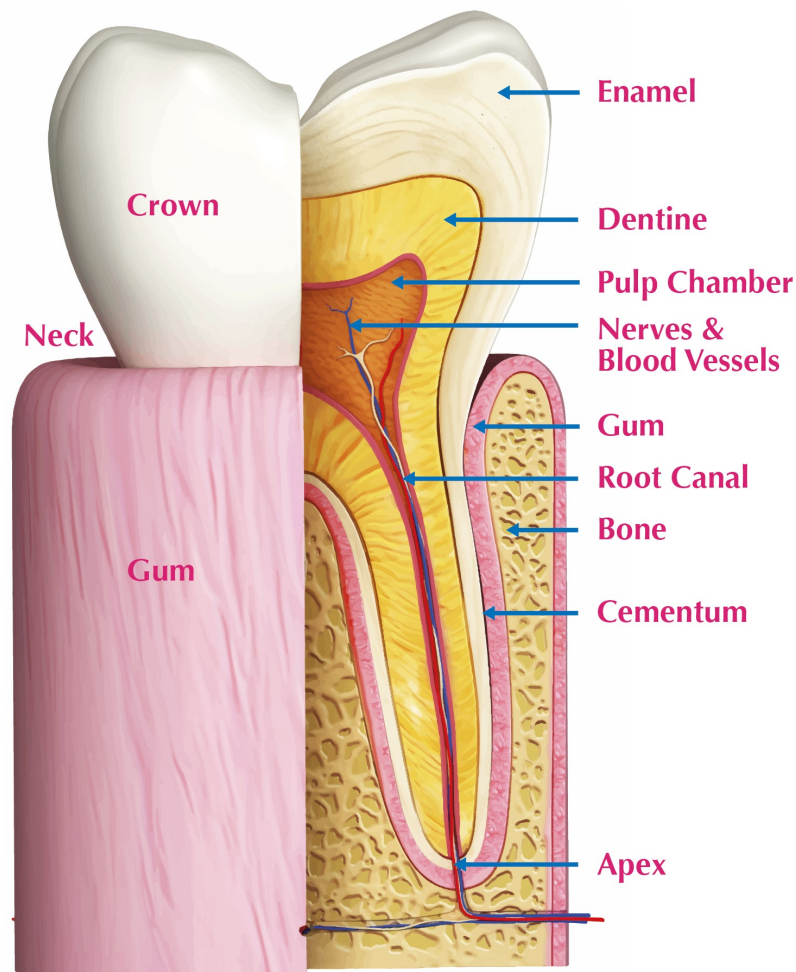
Crown- The crown of the tooth is what we see when we smile or look in the mirror. It's the part of the tooth that is visible above the gumline.

Neck- The neck of the tooth is where the crown (visible part) meets the root (the part under the gum)

Root- The root of the tooth is anchored into the jaw bone which holds the teeth in place. Different types of teeth will have different numbers and shapes of root. You will normally find that :

Incisors and canines - Usually have one root

Premolars/molars- Will have either 1,2 or 3 roots depending on where they are located in the mouth.



Tooth tissues and structures

There are four main tissues and substances that form teeth

Enamel

Tooth enamel is the hardest material found in the human body. Enamel protects the sensitive parts of the tooth from damage and guards against wear and tear.

There are no nerves or vessels in enamel, it does not feel pain.

Dentine

A layer of dentine is found under the tooth enamel.

Dentine is much softer than enamel and has a bone like consistency.

It is dentine that gives our teeth a yellow tinge

Dentine is very sensitive and can cause some pain when exposed or damaged

Pulp

The pulp is found in the centre of the tooth and contains all the blood vessels and nerves that keep the tooth alive

The pulp is extremely sensitive to any kind of trauma or damage

Damage to the pulp can result in severe pain and possibly the need for extensive dental treatment.

Cementum

A layer of cementum covers the root of the tooth.

It's main job is to help attach the root of the tooth to the bone in the socket (and the jaw)

A ligament cushions between the cementum and the jawbone which further secures the tooth to the bone

The periodontal ligament is a connective tissue, it contains blood vessels, nerves and bundles of collagen fibers.

It is sensitive to pressure and damage. You may experience pain if you are grinding your teeth as this puts pressure onto the periodontal fibers.